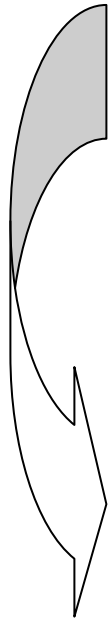


Attachment 1: “Translation” And Analysis of a Paper Case by an Expert

Description of a 47 year-old woman with a nodular mass on her flank			
History	Past medical history	Family History	Social History
<p>The patient first noticed a red plaque-like lesion on her left flank approximately 18 months ago. The lesion has never been tender or itchy. She has applied moisture lotion without improvement. Over the last 6 months, the lesion has become more raised and there was significant growth during the last 4 weeks. The patient denies any other health problems.</p>	<p>She underwent a hysterectomy in 1991 for multiple leiomyomas. Takes HRT and Tylenol as needed</p>	<p>The patient has three grown children, all alive and well. Her father is 70 years-old and suffers from atherosclerosis, and underwent a 3-vessel CABG at 58. Her mother died at the age of 40 from “womanly cancer”.</p>	<p>Married 27 years, school librarian, no smoking, social drinker.</p>



Expert categorical translation	
History	Physical Findings
<ul style="list-style-type: none"> • Persistent, progressive, nonpruritic, non-tender. • Location - lesions in trunk area not sun induced • Single lesion persistent progressive – Neoplasm • Past medical history not remarkable 	<ul style="list-style-type: none"> • Poorly demarcated exophytic nodule • Color irregularity and border irregularity and satellitosis. • Lesions around the primary lesion usually indicate subcutaneous spread. • Some central infarction or necrosis.